

The Use of Imaging in COVID-19

The value of an imaging test relates to the generation of results that are clinically actionable either for establishing a diagnosis or for guiding management, triage, or therapy. That value is diminished by costs that include the risk of radiation exposure to the patient, risk of COVID-19 transmission to uninfected healthcare workers and other patients, consumption of PPE, and need for cleaning and downtime of radiology rooms in resource-constrained environments. The appropriate use of imaging in each of the scenarios was considered on this basis.

This statement focuses exclusively on the use of chest radiography (CXR) and computed tomography of the thorax (CT). While ultrasound has been suggested as a potential triage and diagnostic tool for COVID-19 given the predilection for the disease in subpleural regions, there is limited experience at this time (16), as well as infection control issues.

CXR is insensitive in mild or early COVID-19 infection (17). However, with respect to the relative value of CXR or CT for detecting the presence of viral pneumonia, the experience is vastly different dependent upon community norms and public health directives. When patients are encouraged to present early in the course of their disease, as was the case in Wuhan, China, CXR has little value. The greater sensitivity of CT for early pneumonic changes is more relevant in the setting of a public health approach that required isolation of all infected patients within an environment where the reliability of COVID-19 testing was limited and turnaround times were long (4). Alternatively, in New York City where patients were instructed to stay at home until they experienced advanced symptoms, CXR was often abnormal at the time of presentation. Equipment portability with imaging performed within an infected patient's isolation room is another factor that may favor CXR in selected populations, effectively eliminating the risk of COVID-19 transmission along the transport route to a CT scanner and within the room housing a CT scanner, particularly in environments lacking PPE. In hospitalized patients CXR can be useful for assessing disease progression and alternative diagnoses such as lobar pneumonia, suggestive of bacterial superinfection, pneumothorax and pleural effusion.

CT is more sensitive for early parenchymal lung disease, disease progression, and alternative diagnoses including acute heart failure from COVID-19 myocardial injury (18) and when

acquired with intravenous contrast material, pulmonary thromboembolism. Leveraging these superior capabilities depends upon the availability of CT capacity, particularly considering the potential reduction in CT scanner availability due to the additional time required to clean and disinfect equipment following imaging of patients with suspected COVID-19. Some centers rely on the improved depiction of COVID-19 findings with CT relative to CXR (19) and their association with clinical worsening to determine patient disposition to home, hospital admission, or intensive care. In recognition of variance amongst local practice patterns and resource availability, it is important to state at the outset that the scenarios specify the use of imaging but do *not* articulate the relative merit of CXR versus CT. Ultimately, the choice of imaging modality is left to the judgement of clinical teams at the point-of-care accounting for the differing attributes of CXR and CT, local resources, and expertise.

Overview of Clinical Scenarios

The scenarios apply only to patients presenting with features consistent with COVID-19 infection. The severity of respiratory disease and pre-test probability of COVID-19 infection are specified for each scenario, with additional key considerations including the presence of risk factors for disease progression, evidence of disease progression, and the presence of significant critical resource constraints (**Table 1**). The scenarios distinguish mild respiratory disease from moderate-to-severe respiratory disease based on the absence vs. presence of significant pulmonary dysfunction or damage. Pre-test probability is defined by the background prevalence of infection and can be estimated by observed transmission patterns: low by sporadic transmission; moderate by clustered transmission; and high by community transmission (20). Individual pre-test probability is further modified if there is known exposure through contact with a confirmed case of COVID-19 (21). For health care providers, the CDC categorizes medical-related exposures into low, medium, and high-risk groups (22). Within a diagnostic radiology department, brief (a few minutes or less) unprotected interaction with a patient with COVID-19 as well as prolonged close contact with a masked, infected patient by a medical provider wearing PPE are categorized as low-risk exposures (21, 22). Risk factors for poor outcomes in patients with COVID-19 infection are considered separately from pre-test

probability, with common risk factors including age > 65 years, cardiovascular disease, diabetes, chronic respiratory disease, hypertension, and immune-compromised (23). Identifying a patient as being at high risk for COVID-19 progression is not necessarily a feature of any single risk factor, but is rather a clinical judgement based on the combination of underlying comorbidities and general health status that suggests a higher level of clinical concern. Where appropriate, management variations based upon risk factors for disease progression are called out explicitly, as in Scenario 1. All clinical scenarios begin by characterizing COVID-19 status based upon the availability of laboratory test results.

Scenario 1: Mild Features of COVID-19

The first scenario (**Fig 1**) addresses a patient presenting for evaluation at an outpatient clinic or via telehealth with mild respiratory features consistent with COVID-19 infection, any pre-test probability of COVID-19 infection, and no significant critical resource constraints. When COVID-19 test results are unavailable, patients with moderate-to-high pre-test probability should be initially managed as if COVID-19 testing is positive, while patients with low pre-test probability should be initially managed as if COVID-19 testing is negative. Imaging is advised for patients with risk factors for COVID-19 progression and either positive COVID-19 testing or moderate-to-high pre-test probability in the absence of COVID-19 testing (**Fig 1, Q1**). Imaging provides a baseline for future comparison, may establish manifestations of important comorbidities in patients with risk factors for disease progression (**Table 1**), and may influence the intensity of monitoring for clinical worsening. Imaging is not advised for patients with mild features who are COVID-19 positive without accompanying risk factors for disease progression, or for patients with mild features who are COVID-19 negative (**Fig 1, Q2 & Q3**). The panel felt that the yield of imaging in these settings would be very low and that it was safe for most patients to self-monitor for clinical worsening. Regardless of COVID-19 test results and risk factors, imaging is advised for patients with mild clinical features who subsequently develop clinical worsening (**Fig 1, Q4 & Q5**). In the absence of clinical worsening, management involves support and isolation of patients with positive COVID-19 testing or patients with moderate to high pre-test probability without COVID-19 test results available.

Although not specifically addressed by this scenario, in the presence of significant resources constraints, there is no role for imaging of patients with mild features of COVID-19.

Scenario 2: Moderate to Severe Features of COVID-19

The second scenario (**Fig 2**) addresses a patient presenting with moderate-to-severe features consistent with COVID-19 infection, any pre-test probability of COVID-19 infection, and no significant critical resource constraints. Separate ratings were obtained for COVID-19 positive patients and either COVID-19 negative patients or patients for whom COVID-19 testing is unavailable (**Fig 2, Q6 & Q7**). Imaging is advised regardless of the results or availability of COVID-19 testing given the impact of imaging in both circumstances.

For COVID-19 positive patients, imaging establishes baseline pulmonary status and identifies underlying cardiopulmonary abnormalities that may facilitate risk stratification for clinical worsening. In the presence of clinical worsening, imaging is again advised to assess for COVID-19 progression or secondary cardiopulmonary abnormalities such as pulmonary embolism, superimposed bacterial pneumonia, or heart failure that can potentially be secondary to COVID-19 myocardial injury (**Fig 2, Q8**).

For COVID-19 negative patients or any patient for whom testing is not performed, imaging may reveal an alternative diagnosis to explain the patient's clinical features, which should direct patient care as per existing clinical guidelines or standard clinical practice. If an alternative diagnosis is not revealed or images demonstrate features of COVID-19 infection, then subsequent clinical evaluation would depend upon the pre-test probability of COVID-19 infection and COVID-19 test availability. Falsely negative COVID-19 testing is more prevalent in high pre-test probability circumstances and repeat COVID-19 testing is therefore advised if available. Depending upon the imaging findings, other clinical investigations may be pursued.

Scenario 3: Moderate-to-Severe Features of COVID-19 in a Resource Constrained Environment

The third scenario (**Fig 3**) addresses a patient presenting with moderate-to-severe features consistent with COVID-19 infection within an environment of high community disease burden and critical resource limitations as seen in Wuhan, China, in regions of Italy and Spain, and in New York City. Because healthcare personnel and infrastructure may be overwhelmed by a high influx of new patients and resources are limited to provide critical care, urgent decision-making and triage are of primary importance. At the time of this writing, turnaround times for COVID-19 test results range from 6 to over 48 hours with most sites waiting at least 12 hours for results. This is an impractically long time period to consider triage to limited hospital beds and ventilators. However, rapid point-of-care (PoC) COVID-19 tests are expected to be released into clinical environments during the first week of April 2020, providing routine turnaround times of less than an hour and potentially as little as 5 minutes (24-27). While the initial availability and sample processing capacity of PoC COVID-19 testing is expected to be limited, this should increase over time.

The third scenario first considers the potential availability of PoC COVID-19 testing. Imaging is advised when PoC COVID-19 testing is available and positive (**Fig 3, Q9**) for the same reasons as described for Scenario 2. Based upon imaging findings and clinical features, patients are subsequently supported and monitored with a level of intensity consistent with clinical features. Imaging is again indicated if patients subsequently clinically worsen (**Fig 3, Q11**).

Imaging is advised to support more rapid triage of patients in a resource-constrained setting when PoC COVID-19 testing is not available or negative (**Fig 3, Q10**). Imaging may reveal features of COVID-19, which within this scenario may be taken as a presumptive diagnosis of COVID-19 for medical triage and associated decisions regarding disposition, infection control, and clinical management. In this high pre-test probability environment, and as described for Scenario 2, the possibility of falsely negative COVID-19 testing creates a circumstance where a COVID-19 diagnosis may be presumed when imaging findings are strongly suggestive of COVID-

19 despite negative COVID-19 testing. This guidance represents a variance from other published recommendations which advise against the use of imaging for the initial diagnosis of COVID-19 (28) and was supported by direct experience amongst panelists providing care within the conditions described for this scenario. The relationship between disease severity and triage may need to be fluid depending upon resources and case load. When imaging reveals an alternative diagnosis to COVID-19, management is based upon established guidelines or standard clinical practice.

Additional Key Questions:

Daily chest radiographs are not indicated in stable intubated patients with COVID-19 (Q12)

Multiple studies have shown no difference in important outcomes (mortality, length of stay, and ventilator days) for intensive care unit patients imaged on-demand as compared to a daily routine protocol (29-32). Avoidance of non-value-added imaging is particularly important in the COVID-19 patient population to minimize exposure risk of radiology technologists and to conserve PPE.

CT scan is indicated in a patient who has functional impairment and/or hypoxemia after recovery from COVID-19 (Q13)

With the recent emergence of SARS-CoV2 as a human pathogen, there are no long-term follow-up studies of survivors. Postmortem evaluation of a single patient who succumbed to severe COVID-19 showed pathologic findings consistent with diffuse alveolar damage, similar to findings previously described with severe acute respiratory syndrome (SARS) and Middle East respiratory syndrome (MERS) (33). Patients with functional impairment following recovery from COVID-19 should undergo imaging to differentiate between expected morphologic abnormalities as sequelae of infection, mechanical ventilation, or both versus a different and potentially treatable process.

COVID-19 testing is indicated in a patient who is found incidentally to have typical findings of COVID-19 on a CT scan. (Q14)

While CT findings of COVID-19 infection are nonspecific, their presence in an asymptomatic patient with no or mild respiratory symptoms is concerning in a setting of known community transmission, particularly if there is no better alternative diagnosis. Asymptomatic carriers of COVID-19 have been estimated to comprise 17.9% - 33.3% of all infected cases (34, 35). Asymptomatic infection with suggestive CT findings in the lung has been documented in screened cruise ship passengers (11). It is believed that the presence of undetected infected and mildly symptomatic or asymptomatic individuals may be contributing to the rapid geographic spread of SARS-CoV2 (9). RT-PCR testing in this scenario is important to potentially identify an occult infection and limit further transmission both within the community and in the environment where the patient is receiving medical care. In highly prevalent areas, an additional uncertainty is whether CT should be used as a screening tool either as a stand-alone or as an adjunct to RT-PCR to exclude occult infection prior to surgery or intensive immunosuppressive therapies.

The panel's ratings are provided in **Figure 4**, and a summary of all recommendations is provided in **Table 2**.

Additional Resources

For purposes of image interpretation and reporting, readers are referred to a recently published systematic review of imaging findings of COVID-19 (36) and a multi-society consensus paper on reporting chest CT findings related to COVID-19 (37). As an aid to improving radiologist and pulmonologist familiarity with the imaging findings of COVID-19, we provide the following link (<https://www.fleischner-covid19.org>) to the Fleischner Society website where an educational repository of proven COVID-19 cases can be found.

Conclusion

This statement is intended to offer guidance to physicians on the use of thoracic imaging across a breadth of healthcare environments. It represents the collective opinions and perspectives of thoracic radiology, pulmonology, intensive care, emergency medicine, laboratory medicine, and infection control experts practicing in 10 countries, representative of the highest burden of COVID-19 worldwide. It also represents opinion at a moment in time within a highly-dynamic environment where the status of regional epidemics and the availability of critical resources to combat those epidemics vary daily. The evidence base supporting the use of imaging across the scenarios presented is scant and the advice presented herein may undergo refinement through rigorous scientific investigation, exposing nuances of image interpretation that may lead to prognostic information and guide management decisions. At the time of this writing, no therapy has been confirmed to alter the course of COVID-19, there is no known cure, and there is no vaccine for prevention. As effective treatments are developed, thoracic imaging may find new roles by establishing treatment response or characterizing patients as likely responders to novel therapies.

References

1. World Health Organization: Director-General's opening remarks at the media briefing on COVID-19 - 11 March 2020. <https://www.who.int/dg/speeches/detail/who-director-general-s-opening-remarks-at-the-media-briefing-on-covid-19---11-march-2020>. Updated March 11, 2020. Accessed April 1, 2020.
2. World Health Organization: Coronavirus disease (COVID-19) Situation Dashboard. <https://experience.arcgis.com/experience/685d0ace521648f8a5beeeee1b9125cd>. Updated April 1, 2020. Accessed April 1, 2020.
3. Johns Hopkins University: Coronavirus COVID-19 Global Cases by the Center for Systems Science and Engineering (CSSE). <https://gisanddata.maps.arcgis.com/apps/opsdashboard/index.html#/bda7594740fd40299423467b48e9ecf6>. Updated April 1, 2020. Accessed April 1, 2020.
4. Ai T, Yang Z, Hou H, Zhan C, Chen C, Lv W, Tao Q, Sun Z, Xia L. Correlation of Chest CT and RT-PCR Testing in Coronavirus Disease 2019 (COVID-19) in China: A Report of 1014 Cases. *Radiology* 2020;200642. doi: 10.1148/radiol.2020200642
5. Li Y, Yao L, Li J, Chen L, Song Y, Cai Z, Yang C. Stability Issues of RT-PCR Testing of SARS-CoV-2 for Hospitalized Patients Clinically Diagnosed with COVID-19. *J Med Virol* 2020. doi: 10.1002/jmv.25786
6. Wang W, Xu Y, Gao R, Lu R, Han K, Wu G, Tan W. Detection of SARS-CoV-2 in Different Types of Clinical Specimens. *JAMA : the journal of the American Medical Association* 2020. doi: 10.1001/jama.2020.3786
7. Zou L, Ruan F, Huang M, Liang L, Huang H, Hong Z, Yu J, Kang M, Song Y, Xia J, Guo Q, Song T, He J, Yen HL, Peiris M, Wu J. SARS-CoV-2 Viral Load in Upper Respiratory Specimens of Infected Patients. *N Engl J Med* 2020;382(12):1177-1179. doi: 10.1056/NEJMc2001737
8. Fang Y, Zhang H, Xie J, Lin M, Ying L, Pang P, Ji W. Sensitivity of Chest CT for COVID-19: Comparison to RT-PCR. *Radiology* 2020;200432. doi: 10.1148/radiol.2020200432
9. Li R, Pei S, Chen B, Song Y, Zhang T, Yang W, Shaman J. Substantial undocumented infection facilitates the rapid dissemination of novel coronavirus (SARS-CoV2). *Science* 2020. doi: 10.1126/science.abb3221
10. Rothe C, Schunk M, Sothmann P, Bretzel G, Froeschl G, Wallrauch C, Zimmer T, Thiel V, Janke C, Guggemos W, Seilmaier M, Drosten C, Vollmar P, Zwirgmaier K, Zange S, Wolfel R, Hoelscher M. Transmission of 2019-nCoV Infection from an Asymptomatic Contact in Germany. *N Engl J Med* 2020;382(10):970-971. doi: 10.1056/NEJMc2001468
11. Inui S, Fujikawa A, Jitsu M, Kunishima N, Watanabe S, Suzuki Y, Umeda S, Uwabe Y. Chest CT Findings in Cases from the Cruise Ship "Diamond Princess" with Coronavirus Disease 2019 (COVID-19). *Radiology: Cardiothoracic Imaging* 2020;2(2). doi: 10.1148/ryct.2020200110

12. Mossa-Basha M, Meltzer CC, Kim DC, Tuite MJ, Kolli KP, Tan BS. Radiology Department Preparedness for COVID-19: Radiology Scientific Expert Panel. *Radiology* 2020:200988. doi: 10.1148/radiol.2020200988
13. Kooraki S, Hosseiny M, Myers L, Gholamrezanezhad A. Coronavirus (COVID-19) Outbreak: What the Department of Radiology Should Know. *J Am Coll Radiol* 2020. doi: 10.1016/j.jacr.2020.02.008
14. Centers for Disease Control and Prevention: Coronavirus Disease 2019 (COVID-19) Interim Infection Prevention and Control Recommendations. <https://www.cdc.gov/coronavirus/2019-ncov/infection-control/control-recommendations.html#adhere>. Updated April 1, 2020. Accessed April 1, 2020.
15. Dong Y, Mo X, Hu Y, Qi X, Jiang F, Jiang Z, Tong S. Epidemiological Characteristics of 2143 Pediatric Patients With 2019 Coronavirus Disease in China. *Pediatrics* 2020. doi: 10.1542/peds.2020-0702
16. Soldati G, Smargiassi A, Inchingolo R, Buonsenso D, Perrone T, Briganti DF, Perlini S, Torri E, Mariani A, Mossolani EE, Tursi F, Mento F, Demi L. Is there a role for lung ultrasound during the COVID-19 pandemic? *J Ultrasound Med* 2020. doi: 10.1002/jum.15284
17. Wong HYF, Lam HYS, Fong AH, Leung ST, Chin TW, Lo CSY, Lui MM, Lee JCY, Chiu KW, Chung T, Lee EYP, Wan EYF, Hung FNI, Lam TPW, Kuo M, Ng MY. Frequency and Distribution of Chest Radiographic Findings in COVID-19 Positive Patients. *Radiology* 2020:201160. doi: 10.1148/radiol.2020201160
18. Driggin E, Madhavan MV, Bikdeli B, Chuich T, Laracy J, Bondi-Zoccai G, Brown TS, Nigoghossian C, Zidar DA, Haythe J, Brodie D, Beckman JA, Kirtane AJ, Stone GW, Krumholz HM, Parikh SA. Cardiovascular Considerations for Patients, Health Care Workers, and Health Systems During the Coronavirus Disease 2019 (COVID-19) Pandemic. *J Am Coll Cardiol* 2020. doi: 10.1016/j.jacc.2020.03.031
19. Orsi MA, Oliva AG, Cellina M. Radiology Department Preparedness for COVID-19: Facing an Unexpected Outbreak of the Disease. *Radiology* 2020. doi: 10.1148/radiol.2020201214
20. World Health Organization: Critical preparedness, readiness and response actions for COVID-19. <https://www.who.int/emergencies/diseases/novel-coronavirus-2019/technical-guidance/critical-preparedness-readiness-and-response-actions-for-covid-19>. Updated March 22, 2020. Accessed April 1, 2020.
21. Center for Disease Control and Prevention: Coronavirus Disease 2019 (COVID-19) Public Health Recommendations for Community-Related Exposure. <https://www.cdc.gov/coronavirus/2019-ncov/php/public-health-recommendations.html>. Updated March 30, 2020. Accessed April 1, 2020.
22. Center for Disease Control and Prevention: Interim U.S. Guidance for Risk Assessment and Public Health Management of Healthcare Personnel with Potential Exposure in a Healthcare Setting to Patients with Coronavirus Disease (COVID-19). <https://www.cdc.gov/coronavirus/2019-ncov/hcp/guidance-risk-assesment-hcp.html>. Updated March 7, 2020. Accessed April 1, 2020.

23. Wu Z, McGoogan JM. Characteristics of and Important Lessons From the Coronavirus Disease 2019 (COVID-19) Outbreak in China: Summary of a Report of 72314 Cases From the Chinese Center for Disease Control and Prevention. JAMA : the journal of the American Medical Association 2020. doi: 10.1001/jama.2020.2648
24. DiaSorin Molecular: Simplexa COVID-19 Direct Kit. <https://molecular.diasorin.com/us/kit/simplexa-covid-19-direct-kit/>. Accessed April 1, 2020.
25. bioMérieux: First of 3 diagnostic tests for SARS-CoV-2 coronavirus available from bioMérieux. <https://www.biomerieux.com/en/novel-coronavirus-covid-19>. Updated March 11, 2020. Accessed April 1, 2020.
26. Cepheid: Xpert® Xpress SARS-CoV-2 has received FDA Emergency Use Authorization. <https://www.cepheid.com/coronavirus>. Accessed April 1, 2020.
27. Abbott: ID NOW COVID-19 Molecular. In minutes. On the front line. <https://www.alere.com/en/home/product-details/id-now-covid-19.html>. Accessed April 1, 2020.
28. American College of Radiology: ACR Recommendations for the use of Chest Radiography and Computed Tomography (CT) for Suspected COVID-19 Infection. <https://www.acr.org/Advocacy-and-Economics/ACR-Position-Statements/Recommendations-for-Chest-Radiography-and-CT-for-Suspected-COVID19-Infection>. Updated March 22, 2020. Accessed April 1, 2020.
29. Oba Y, Zaza T. Abandoning daily routine chest radiography in the intensive care unit: meta-analysis. Radiology 2010;255(2):386-395. doi: 10.1148/radiol.10090946
30. Hejblum G, Chalumeau-Lemoine L, loos V, Boelle PY, Salomon L, Simon T, Vibert JF, Guidet B. Comparison of routine and on-demand prescription of chest radiographs in mechanically ventilated adults: a multicentre, cluster-randomised, two-period crossover study. Lancet 2009;374(9702):1687-1693. doi: 10.1016/S0140-6736(09)61459-8
31. Lakhal K, Serveaux-Delous M, Lefrant JY, Capdevila X, Jaber S, AzuRea network for the RadioDay study g. Chest radiographs in 104 French ICUs: current prescription strategies and clinical value (the RadioDay study). Intensive Care Med 2012;38(11):1787-1799. doi: 10.1007/s00134-012-2650-9
32. Suh RD, Genshaft SJ, Kirsch J, Kanne JP, Chung JH, Donnelly EF, Ginsburg ME, Heitkamp DE, Henry TS, Kazerooni EA, Ketani LH, McComb BL, Ravenel JG, Saleh AG, Shah RD, Steiner RM, Mohammed TL. ACR Appropriateness Criteria(R) Intensive Care Unit Patients. Journal of thoracic imaging 2015;30(6):W63-65. doi: 10.1097/RTI.0000000000000174
33. Xu Z, Shi L, Wang Y, Zhang J, Huang L, Zhang C, Liu S, Zhao P, Liu H, Zhu L, Tai Y, Bai C, Gao T, Song J, Xia P, Dong J, Zhao J, Wang FS. Pathological findings of COVID-19 associated with acute respiratory distress syndrome. The lancet Respiratory medicine 2020. doi: 10.1016/S2213-2600(20)30076-X

34. Mizumoto K, Kagaya K, Zarebski A, Chowell G. Estimating the asymptomatic proportion of coronavirus disease 2019 (COVID-19) cases on board the Diamond Princess cruise ship, Yokohama, Japan, 2020. *Euro Surveill* 2020;25(10). doi: 10.2807/1560-7917.ES.2020.25.10.2000180
35. Nishiura H, Kobayashi T, Suzuki A, Jung SM, Hayashi K, Kinoshita R, Yang Y, Yuan B, Akhmetzhanov AR, Linton NM, Miyama T. Estimation of the asymptomatic ratio of novel coronavirus infections (COVID-19). *Int J Infect Dis* 2020. doi: 10.1016/j.ijid.2020.03.020
36. Salehi S, Abedi A, Balakrishnan S, Gholamrezanezhad A. Coronavirus Disease 2019 (COVID-19): A Systematic Review of Imaging Findings in 919 Patients. *AJR American journal of roentgenology* 2020:1-7. doi: 10.2214/AJR.20.23034
37. Simpson S, Kay FU, Abbara A, Bhalla S, Chung JH, Chung M, Henry TS, Kanne JP, Kligerman S, Ko JP, Litt H. Radiological Society of North America Expert Consensus Statement on Reporting Chest CT Findings Related to COVID-19. Endorsed by the Society of Thoracic Radiology, the American College of Radiology, and RSNA. *Radiology: Cardiothoracic Imaging* 2020;2(2). doi: 10.1148/ryct.2020200152

Table 1. Definitions and Criteria for Key Components of Common Clinical Scenarios

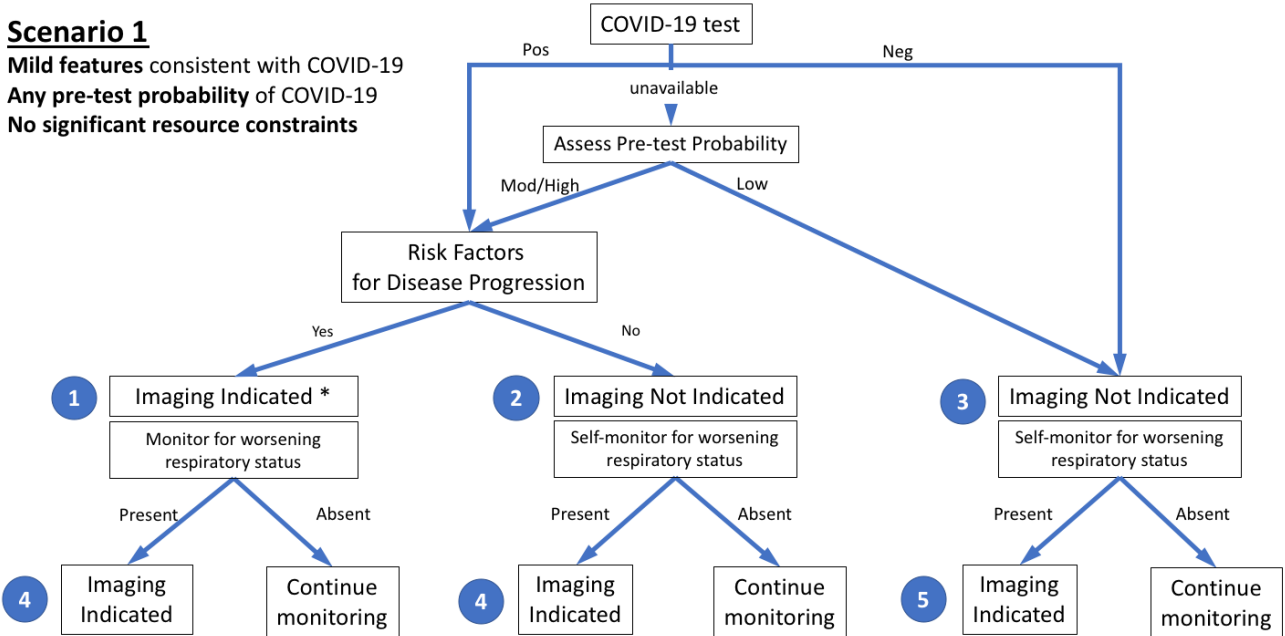
Definitions and criteria for key components of common clinical scenarios
Severity of respiratory disease
<input type="checkbox"/> Mild: No evidence of significant pulmonary dysfunction or damage (e.g., absence of hypoxemia, no or mild dyspnea)
<input type="checkbox"/> Moderate-to-severe: Evidence of significant pulmonary dysfunction or damage (e.g., hypoxemia, moderate-to-severe dyspnea)
Pre-test probability
<input type="checkbox"/> Based upon background prevalence of disease as estimated by observed transmission patterns. May be further modified by individual’s exposure risk. Sub-categorized as:
<input type="radio"/> Low: Sporadic transmission
<input type="radio"/> Medium: Clustered transmission
<input type="radio"/> High: Community transmission
Risk factors for disease progression
<input type="checkbox"/> Present: Clinical judgement regarding combination of age > 65 years and presence of comorbidities (e.g., cardiovascular disease, diabetes, chronic respiratory disease, hypertension, immune-compromised)
<input type="checkbox"/> Absent: Defined by the absence of risk factors for disease progression
Disease progression
<input type="checkbox"/> Progression of mild disease to moderate-to-severe disease as defined above.
<input type="checkbox"/> Progression of moderate-to-severe disease with worsening objective measures of hypoxemia.
Resource constraints
<input type="checkbox"/> Limited access to personnel, personal protective equipment, COVID-19 testing ability (including swabs, reagent, or personnel), hospital beds, and/or ventilators with the need to rapidly triage patients.

Table 2. Summary of Recommendations for Imaging

Summary of Recommendations for Imaging
Main Recommendations
<input type="checkbox"/> Imaging is not routinely indicated as a screening test for COVID-19 in asymptomatic individuals
<input type="checkbox"/> Imaging is not indicated for patients with mild features of COVID-19 unless they are at risk for disease progression (Scenario 1)
<input type="checkbox"/> Imaging is indicated for patients with moderate to severe features of COVID-19 regardless of COVID-19 test results (Scenarios 2 and 3)
<input type="checkbox"/> Imaging is indicated for patients with COVID-19 and evidence of worsening respiratory status (Scenarios 1, 2, and 3)
<input type="checkbox"/> In a resource constrained environment where access to CT is limited, CXR may be preferred for patients with COVID-19 unless features of respiratory worsening warrant the use of CT (Scenarios 2 and 3)
Additional Recommendations
<input type="checkbox"/> Daily chest radiographs are NOT indicated in stable intubated patients with COVID-19
<input type="checkbox"/> CT is indicated in patients with functional impairment and/or hypoxemia after recovery from COVID-19
<input type="checkbox"/> COVID-19 testing is indicated in patients incidentally found to have findings suggestive of COVID-19 on a CT scan

Scenario 1

Mild features consistent with COVID-19
Any pre-test probability of COVID-19
No significant resource constraints



* Clinical judgement should dictate the use of imaging through consideration of patient risk factors and local resources.

Figure 1: The first of three clinical scenarios presented to the panel with final recommendations. Mild features refer to absence of significant pulmonary dysfunction or damage. Pre-test probability is based upon background prevalence of disease and may be further modified by individual's exposure risk. The absence of resource constraints corresponds to sufficient availability of personnel, personal protective equipment, COVID-19 testing, hospital beds, and/or ventilators with the need to rapidly triage patients. Numbers in blue circles indicate key questions referenced in the text and presented in Figure 4. Contextual detail and considerations for imaging with CXR (chest radiography) versus CT (computed tomography) are presented in the text. (Pos=positive, Neg=negative, Mod=moderate). [Although not covered by this scenario and not shown in the figure, in the presence of significant resources constraints, there is no role for imaging of patients with mild features of COVID-19.]

Scenario 2

Moderate to severe features consistent with COVID-19

Any pre-test probability of COVID-19

No significant resource constraints

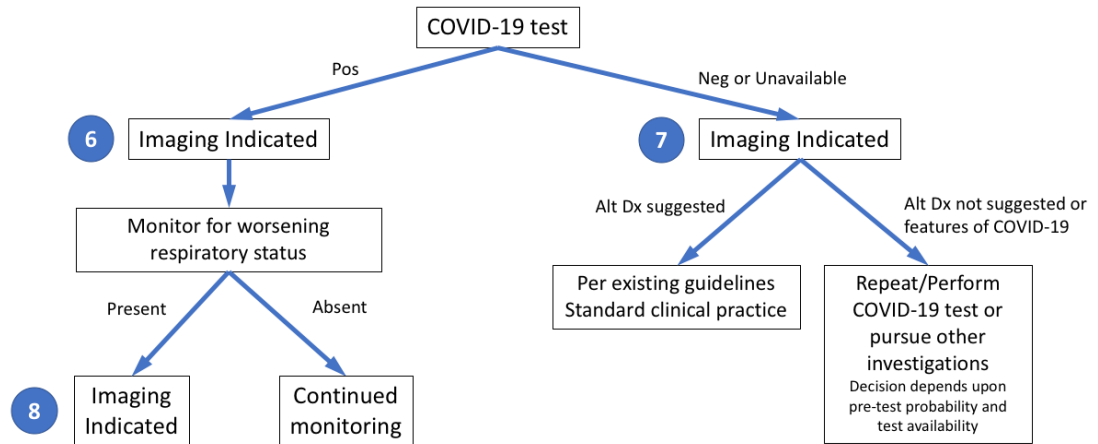


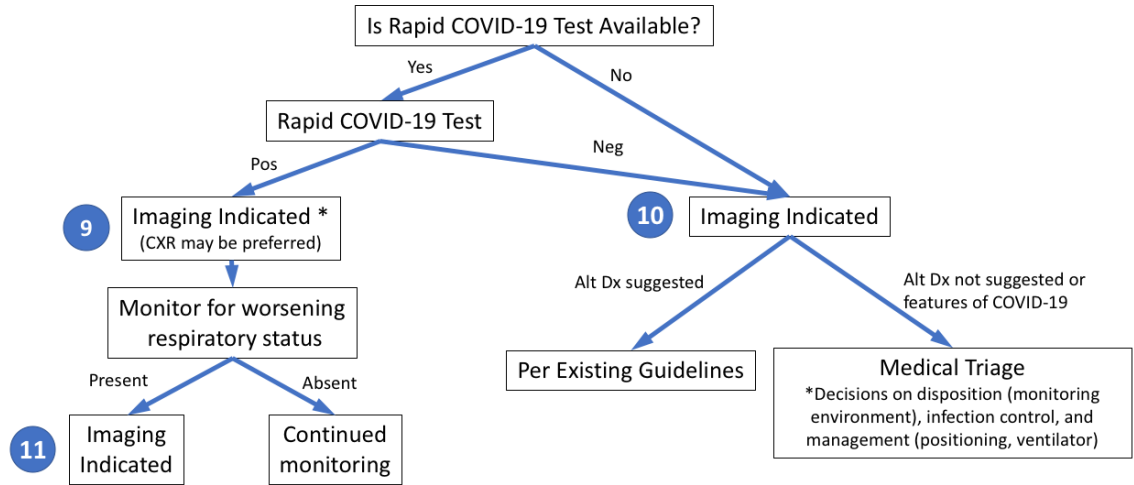
Figure 2: The second of three clinical scenarios presented to the panel with final recommendations. Moderate-to-severe features refer to evidence of significant pulmonary dysfunction or damage. Pre-test probability is based upon background prevalence of disease and may be further modified by individual's exposure risk. The absence of resource constraints corresponds to sufficient availability of personnel, personal protective equipment, COVID-19 testing, hospital beds, and/or ventilators with the need to rapidly triage patients. Numbers in blue circles indicate key questions referenced in the text and presented in Figure 4. Contextual detail and considerations for imaging with CXR (chest radiography) versus CT (computed tomography) are presented in the text. (Pos=positive, Neg=negative, Alt Dx=alternate diagnosis).

Scenario 3

Moderate to severe features consistent with COVID-19

High pre-test probability of COVID-19

Resource constrained (Need for urgent patient triage due to lack of resources – beds, ventilators, medical personnel, PPE, COVID tests)



* Lower priority if severely resource constrained, relative to 10 or 11.

Figure 3: The third of three clinical scenarios presented to the panel with final recommendations. Moderate-to-severe features refer to evidence of significant pulmonary dysfunction or damage. High pre-test probability is based upon high background prevalence of disease associated with community transmission. Rapid COVID-19 test is a point-of-care test with a less than one-hour turnaround time. Numbers in blue circles indicate key questions referenced in the text and presented in Figure 4. Contextual detail and considerations for imaging with CXR (chest radiography) versus CT (computed tomography) are presented in the text. (Pos=positive, Neg=negative, Alt Dx=alternate diagnosis).

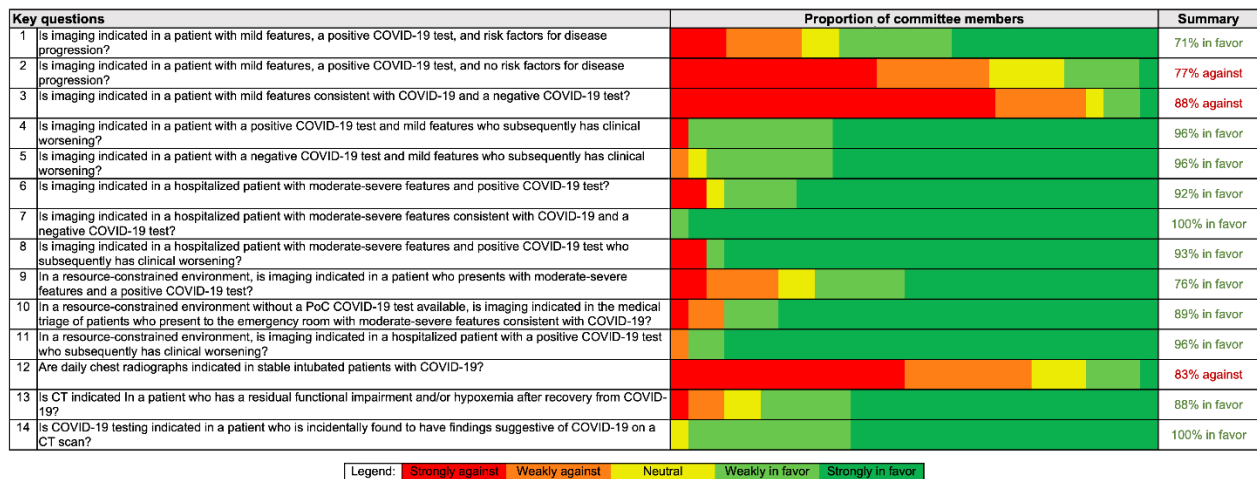

Figure 4: Panel members (total n=27) developed 14 key questions (numerals in left column correspond to question numbers in text and Figures 1-3) that were used to support creation of common scenarios and recommendations related to the use of chest imaging in patients with features of COVID-19. The proportion of panel member votes for each question is presented on a 5-point scale, as well as a summary column that shows the total percentage who voted for or against imaging for each key question, excluding those members who were neutral or who abstained (1 panel member abstained for questions 1 and 2).